SIRIRAJ DERMATOLOGY ANNUAL Meeting 2024

Skin signs in systemic diseases: From head to toe

รศ.พญ.เพ็ญวดี พัฒนปรีชากุล
รศ.นพ.สุมนัส บุณยะรัตเวช
ภาควิชาตจวิทยา คณะแพทยศาสตร์ศิริราชพยาบาล

Dermatology Essentials
Mastering the Basic
for Professional Practice

17 JAN 2024

SIRIRAJ DERMATOLOGY ANNUAL Meeting 2024

Introduction

- Skin: "body's largest external organ"→ visible signs of illness (skin diseases and skin signs in systemic diseases)
- Signs & Symptoms
- Signs: "rash" as a presenting complaint
- **Inspection**, **Palpation**, ~~*Auscultation*~~, *and* ~~*Percussion*~~
- Lighting

SIRIRAJ DERMATOLOGY ANNUAL Meeting 2024

Introduction

- Inspection note features: location, symmetry, arrangement, color, scaling, dryness, surface features, borders, size, shape and contour of lesions
- Not only exam with presenting lesion
- Don't forget to also inspect the scalp, hair, mouth, mucosa and nails, (± whole body examination), back/buttock
- Evolution of the skin lesions

Evolution + Variation

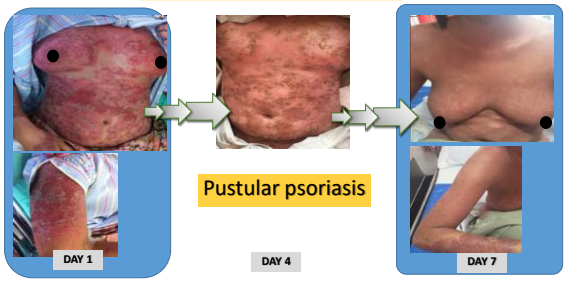

Pustular psoriasis

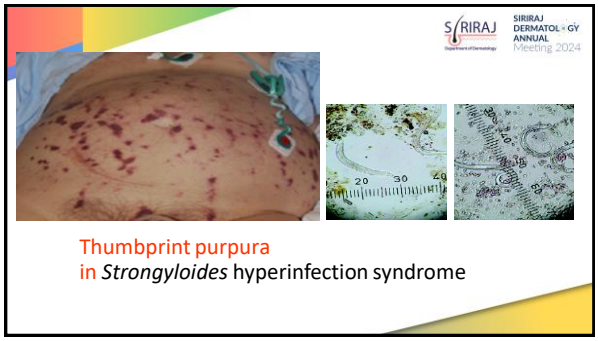

Thumbprint purpura
in *Strongyloides* hyperinfection syndrome

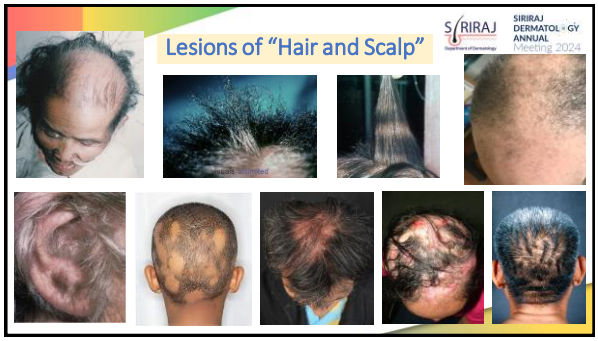

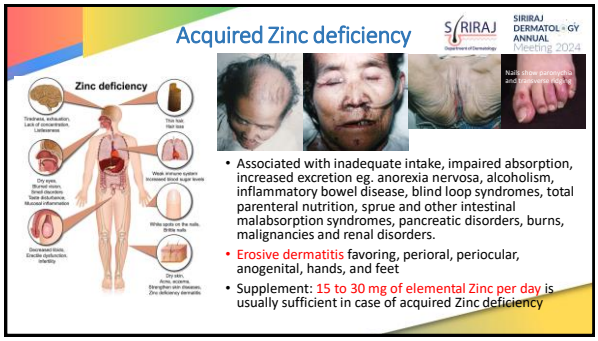

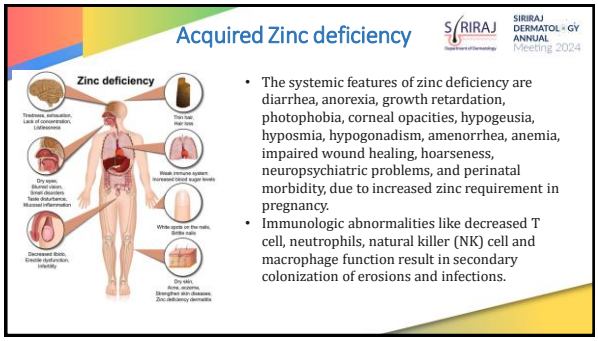

Acquired Zinc deficiency

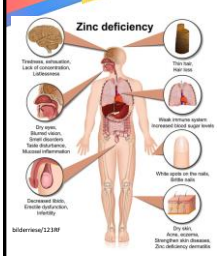

Clearance of lesions following zinc therapy after 2 weeks

Indian J Dermatol. 2012; 57: 492–494.

Flag signs: Kwashiorkor (Protein-energy malnutrition)

- Lacquered flaky paint
- Crazy pavement dermatosis
- Erosions and scaling in kwashiorkor
  - Flaky paint
  - Crazy paving
  - Enamel paint

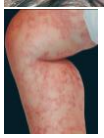

Scurvy (Vitamin C deficiency)

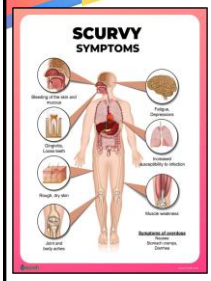

- Perifollicular erythema, hemorrhage
- Corkscrew hair
- Keratosis pilaris like, xerotic skin
- Gum hypertrophy, bleeding per gum, upper GI bleeding

Hypertrichosis lanuginosa acquisita

- The most frequently associated cancers include lung, breast and uterine cancers, colorectal cancer, lymphoma, and bladder cancer
- Often occurs late in the course of the cancer
- Less commonly associated with non-malignant disease such as malnutrition associated with anorexia nervosa, hyperthyroidism, AIDS
- A side effect of drugs such as ciclosporin, phenytoin, interferon, spironolactone, and corticosteroids

Alopecia areata

SIRIRAJ DERMATOLOGY ANNUAL Meeting 2024

- Patchy or diffuse non-scarring alopecia
- Associated with autoimmune disorder including diabetes, lupus erythematosus, and thyroid disease

Alopecia totalis

Exclamation mark hairs

PRIDE Syndrome

SIRIRAJ DERMATOLOGY ANNUAL Meeting 2024

SirirajDerm

PRIDE SYNDROME
COMMON EGFRI-RELATED CUTANEOUS TOXICITIES

Papulopustular Paronychia	Regulatory abnormalities of hair	Itching	Dryness	Due to EGFRis

Scarring alopecia: Discoid lupus erythematosus

SIRIRAJ DERMATOLOGY ANNUAL Meeting 2024

- Chronic cutaneous LE
- Sharply dermacated coin-shaped erythematous plaque
- Cover by prominent **adherent scale** that extend into orifice of dilate hair follicle
- Expand peripheral, central atrophic, telangiectasia, hypopigmentation

Carpet tack sign in DLE

Cutaneous lupus erythematosus Specific LE lesions

SIRIRAJ DERMATOLOGY ANNUAL Meeting 2024

- **Acute cutaneous LE (ACLE)**
  - Morbilliform rash
  - Photosensitive dermatitis
  - Malar rash
  - Oral ulcer

- **Subacute cutaneous LE (SCLE)**
  - Papulosquamous SCLE
  - Annular SCLE

Neonatal LE

- **Chronic cutaneous LE (CCLE)**
  - Classic discoid LE (DLE) localized, generalized
  - Hypertrophic DLE
  - Lupus profundus/lupus panniculitis
  - Mucosal DLE
  - Lupus tumidus
  - Chilblain LE
  - Lichenoid LE

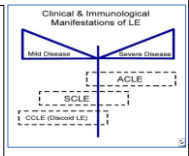

Cutaneous lupus erythematosus Non-specific LE lesions

SIRIRAJ DERMATOLOGY ANNUAL Meeting 2024

- **Cutaneous vascular diseases**
  - Vasculitis; LCV, PAN
  - Vasculopathy
  - Periungual telangiectasia
  - Livedo reticularis
  - Thrombophlebitis
  - Raynaud phenomenon
  - Erythromelalgia

- **Non-scarring alopecia**
  - Lupus hair
  - Telogen effluvium
  - Alopecia areata

- **Non-specific LE lesions**
  - Sclerodactyly
  - Rheumatoid nodule
  - Calcinosis cutis
  - LE- non specific bullous lesion
  - Urticaria
  - Papulonodular mucinosis
  - Cutis laxa
  - Acanthosis nigricans
  - Erythema multiforme
  - Leg ulcer
  - Lichen planus

Acromegaly

SIRIRAJ DERMATOLOGY ANNUAL Meeting 2024

Cutis verticis gyrata

- Hyperplasia of epidermis and dermis "too much skin"
- Coarse facies, furrow and accentuation of fold, cutis verticis gyrata
- Enlarged and protruding of lower lip
- Macroglossia
- Enlargement of the nose, chin, hands and fingers
- Cutis verticis gyrata can be associated with
  - Pachydermoperiostosis (idiopathic hypertrophic osteoarthropathy), scleromyxedema, leukemia, lymphoma, syphilis, Ehlers-Danlos syndrome, cutis laxa, Turner syndrome, Klinefelter syndrome, Noonan syndrome, etc

Nails in systemic diseases

SIRIRAJ DERMATOLOGY ANNUAL Meeting 2024

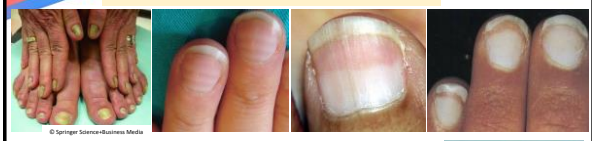

© Springer Science+Business Media

SIRIRAJ DERMATOLOGY ANNUAL Meeting 2024

Yellow nail syndrome

- **Pathogenesis: Unknown**
- **Clinical traids**

(1) Slow-growing, hard, yellow, and dystrophic nails
(2) Lymphedema
(3) Respiratory tract diseases
  - **Chronic bronchitis , bronchiectasis, sinusitis, pleural effusion**

- **Treatment**
  - **No effective treatment**

© Springer Science+Business Media

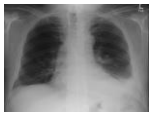

Figure 2 – Image: Stewing, lymphedema and unspecified nails

SIRIRAJ DERMATOLOGY ANNUAL Meeting 2024

Muehrcke's lines in hypoalbuminemia



- White transverse bands
- Do not move distally with the growth of the nail
- Disappear after compression of the fingertip
  - Apparent leukonychia
- Associated with severe serum hypoalbuminemia

SIRIRAJ DERMATOLOGY ANNUAL Meeting 2024

Uremic half and half nails and Terry nails

Half and half nails

Terry nails

- Apparent leukonychia
- Uremic half and half nails (Lindsay nails)
  - 20-50% of patients with chronic kidney disease
  - may also occur in Crohn's disease, Behcet's disease, pellagra, Kawasaki disease, cirrhosis, and healthy persons
- Terry nails
  - Cirrhosis
  - Congestive heart failure
  - Diabetes
  - Kidney failure
  - Viral hepatitis

SIRIRAJ DERMATOLOGY ANNUAL Meeting 2024

Beau's line and Onychomadesis

Beau's line

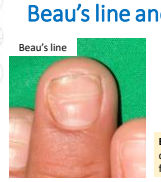

Onychomadesis

Pathogenesis:

- Severe stress interrupts nail growth
- Injuries damage nail matrix

Beau's line: Transverse deep grooved lines on the fingernail or the toenail

Onychomadesis: Proximal separation of the nail plate from the nail matrix due to a temporary cessation of nail growth

Causes of Onychomadesis

Etiology	Possible Causes
Infectious	Hand-foot-and-mouth disease, varicella infection, scarlet fever, fungal infections
Systemic/ dermatologic	Periungual dermatitis, Stevens-Johnson syndrome, toxic epidermal necrolysis, lichen planus, Kawasaki disease
Drug related	Chemotherapeutic agents, valproic acid, carbamazepine, lithium, azithromycin
Other	Nail trauma, familial causes, idopathic causes

Splinter hemorrhage

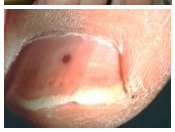

- 15% of infectious endocarditis cases
- Proximally located in IE
- Pathogenesis: small vasculitis or microemboli
- Causes of splinter hemorrhage
  - Minor trauma
  - PRP, psoriasis
  - Onychomycosis
  - Endocarditis
  - Vasculitis
  - Trichinosis
  - Antiphospholipid syndrome
  - Thyrotoxicosis
  - Drug induce
  - Internal malignancy
  - Scurvy
  - Idiopathic

Plummer's nails in Hyperthyroidism



- Onycholysis, or separation of the nail from the nail bed
- Commonly affecting the ring and little fingers
- Occurs in patients with thyrotoxicosis
- 5% of hyperthyroid patients display abnormal nail changes
- Also associated with
  - Psoriasis
  - Traumatic injury
  - Allergic contact dermatitis

Lesions on "the Face"

Xanthoma

Xanthelasma: 50% with hypercholesterolemia

Tendinous xanthoma

Tuberous xanthoma

Eruptive xanthoma

CMAJ April 10, 2007 176 (8) 1113-1120.

Xanthoma

SIRIRAJ DERMATOLOGY ANNUAL Meeting 2024

Xanthoma striatum palmare

Corneal arcus

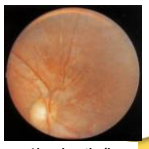

Lipemia retinalis

Xanthoma

SIRIRAJ DERMATOLOGY ANNUAL Meeting 2024

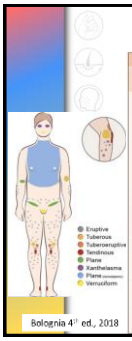

IMPORTANT HYPERLIPOPROTEINEMIAS

Type	Pathogenesis	Laboratory findings	Clinical findings: Skin types of xanthomas	Clinical findings: Systemic
Type I (familial LPL deficiency, familial hypercholyomicronemia)	(a) Deficient or abnormal LPL (AR) (b) Apo C-II deficiency (AR) (c) Deficient glycosyl-phosphatidylinositol-anchored HDL-binding protein 1 (GPIHBP1) (AR) (d) Apo A-V deficiency (AR)	Slow chylomicron clearance Reduced LDL and HDL levels **Hypertriglyceridemia**	Eruptive	No increased risk of coronary artery disease Recurrent pancreatitis
Type II (familial hypercholesterolemia)	(a) LDL receptor defect (AD)[a] (b) Reduced affinity of LDL for LDL receptor due to dysfunction of apo B-100 (ligand) (AD) (c) Accelerated degradation of LDL receptor due to missense PCSK9 variants (AD) (d) Defective LDL receptor adaptor protein 1 (required for receptor internalization) (AR)	Reduced LDL clearance **Hypercholesterolemia**	Tendinous, tuberoeruptive, tuberous, plane (xanthelasma, intertriginous areas, interdigital web spaces[b])	Atherosclerosis of peripheral and coronary arteries
Type III (familial dysbetalipoproteinemia, remnant removal disease, broad beta disease, apo E deficiency)	Hepatic remnant clearance impaired due to apo E abnormality; vast majority of patients only express the apo E_2 isoform that interacts poorly with the apo E receptor (AR>>AD)	Elevated levels of chylomicron remnants and IDLs **Hypercholesterolemia** **Hypertriglyceridemia**	Tuberoeruptive, tuberous, plane (palmar creases) – most characteristic Tendinous	Atherosclerosis of peripheral and coronary arteries
Type IV (endogenous familial hypertriglyceridemia)	Elevated production of VLDL associated with glucose intolerance and hyperinsulinemia; may be associated with heterozygous variants, e.g. in apo A-V, LPL, or the glucokinase regulator protein.	Increased VLDLs **Hypertriglyceridemia**	Eruptive	Frequently associated with type 2 non-insulin-dependent diabetes mellitus, obesity, alcoholism
Type V	Elevated chylomicrons and VLDLs; may be associated with heterozygous variants, e.g. in apo A-V, LPL, or the glucokinase regulator protein.	Decreased LDLs and HDLs **Hypertriglyceridemia**	Eruptive	Diabetes mellitus

[a]In patients with the *LDLR* 931/4+10.A mutation, the phenotype can be altered by SNPs in the genes that encode apo A-II, cytoplasmic opaque hydrolase 2, or growth hormone receptor.
[b]Gain-of-function mutations cause autosomal dominant hypercholesterolemia[c], whereas loss-of-function mutations (most prevalent in African-Americans) result in low LDL levels[d].
[c]Said to be pathognomonic for homozygous state

Bolognia 4th ed., 2018

Behcet's disease

SIRIRAJ DERMATOLOGY ANNUAL Meeting 2024

- Patient must have oral (aphthous) ulcers (any shape, size, or number at least three times in any twelve-month period) along with two of the following four hallmark symptoms:
- Eye inflammation (iritis, uveitis, retinal vasculitis, cells in the vitreous)
- Genital ulcers (including anal ulcers and spots in the genital region and swollen testicles or epididymitis in men)
- Pathergy reaction (papule >2 mm dia. 24-48 hrs or more after needle-prick). The pathergy test has a specificity of 95 percent to 100 percent, but the results are often negative in American and European
- Skin lesions (papulo-pustules, folliculitis, erythema nodosum, acne in post-adolescents not on corticosteroids)

International criteria for Behcet's disease 2006

Symptom	Score*
Oral ulcer	2
Genital ulcer	2
Ocular manifestation	2
Skin manifestation	1
Vascular manifestation	1
Central nervous system involvement	1
Positive pathergy test	1

*Scoring at least 4 indicates Behcet's disease diagnosis. Pathergy testing is optional, but when it is performed, it is given a score of 1.

Bolognia 4th ed., 2018

Behcet's disease

SIRIRAJ DERMATOLOGY ANNUAL Meeting 2024

SYSTEMIC MANIFESTATIONS OF BEHCET DISEASE

Ocular (leading cause of morbidity)[1,2,18,19]
- Occurs in 90% of patients; favors men, in whom it is more severe
- Can be painful and may lead to blindness
- Retinal vasculitis (more frequently associated with blindness)
- Posterior uveitis (most characteristic ocular finding)
- Anterior uveitis (Fig. 30.10), hypopyon
- Secondary glaucoma, cataracts
- Conjunctivitis, scleritis, keratitis, vitreous hemorrhage, optic neuritis

Joints
- Approximately 50% of patients develop arthritis
- In majority (~80% of patients), duration of attacks is <3 months
- Mono- or polyarthritis and non-erosive
- Most commonly knees, wrists and ankles

Gastrointestinal
- Abdominal pain and/or hemorrhage may be difficult to distinguish from IBD (see Table 26.13)
- Ulcerations* develop within the small bowel (in particular the ileocecal region) as well as the transverse and ascending colon and esophagus; perforation can occur

*Resemble aragenal aphthae

Neurologic
- Usually appears later during the evolution of the disease
- Associated with a poor prognosis
- Acute meningo-encephalitis which may resolve spontaneously
- Cranial nerve palsies
- Brainstem lesions that can induce swallowing difficulties, laughter and crying
- Pyramidal or extrapyramidal signs

Vascular
- Aneurysmal or occlusive arterial disease
- Superficial or deep venous thrombosis

Cardiopulmonary
- Coronary arteritis, valvular disease, myocarditis
- Recurrent ventricular arrhythmias
- Pulmonary artery aneurysms

Renal
- Glomerulonephritis

International criteria for Behcet's disease 2006

Symptom	Score*
Oral ulcer	2
Genital ulcer	2
Ocular manifestation	2
Skin manifestation	1
Vascular manifestation	1
Central nervous system involvement	1
Positive pathergy test	1

*Scoring at least 4 indicates Behcet's disease diagnosis. Pathergy testing is optional, but when it is performed, it is given a score of 1.

Bolognia 4th ed., 2018

Systemic amyloidosis

SIRIRAJ DERMATOLOGY ANNUAL Meeting 2024

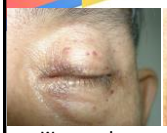

Waxy papules

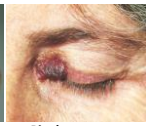

Pinch purpura

Macroglossia

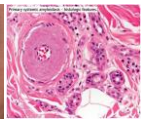

CLINICAL CLASSIFICATION OF AMYLOIDOSIS

Organ-limited (localized) amyloidosis

Cutaneous
- Primary: macular*, lichen*, biphasic*, dyschromic, nodular
- Secondary: incidental finding within various skin tumors (e.g. dermatofibromas, intradermal melanocytic nevi, seborrheic keratoses, adrenal tumors, basal cell carcinomas, Bowen disease, porokeratosis); following PUVA therapy

Endocrine
- Medullary carcinoma of the thyroid, insulinoma, type 2 diabetes

Cerebral
- Alzheimer disease

Systemic amyloidosis

Primary systemic amyloidosis (AL := AH amyloid protein)
- Plasma cell dyscrasias (more common)
- Multiple myeloma-associated

Secondary systemic amyloidosis (reactive; AA amyloid protein)
- Chronic inflammation (e.g. rheumatoid arthritis, hidradenitis suppurativa)
- Chronic infection (e.g. tuberculosis, leprosy)

ATTR amyloidosis (transthyretin amyloid protein**)
- Familial amyloid polyneuropathy (TTR mutations)
- Familial amyloid cardiomyopathy (TTR mutations)
- Wild type ATTR amyloidosis/senile systemic amyloidosis/senile cardiac amyloidosis

ALect2 amyloidosis (leukocyte chemotactic factor 2)

*Seen in patients with Sjögren syndrome.

**Transthyretin is a serum transport protein for thyroxine and retinol-binding protein that is produced in the liver, choroid plexus and eye; orthotopic liver transplantation represents an effective treatment for the inherited forms of ATTR amyloidosis.

Bolognia 4th ed., 2018

Dermatomyositis

SIRIRAJ DERMATOLOGY ANNUAL Meeting 2024

Heliotrope

Gottron's papules

Periungual telangiectasia

Gottron's sign

Poikiloderma at upper back (Shawl sign)

Mechanic hands

Calcinosis cutis

25-30% linked to malignancy

Women: Ovarian and breast CA
Men: GI and respiratory tract CA
Asian: Nasopharyngeal CA

Sturge-Weber Syndrome

SIRIRAJ DERMATOLOGY ANNUAL Meeting 2024

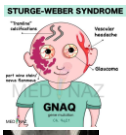

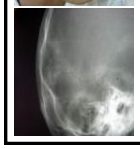

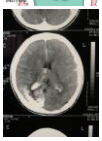

- Sturge-Weber Syndrome–a mesodermal phakomatosis characterized by
  - A port-wine vascular nevus on the upper part of the face
  - Leptomeningeal angiomatosis that involves one or both hemispheres
  - Choroidal vascular lesions associated with glaucoma
  - Early onset seizure, neurologic deterioration and eventual neurodevelopmental delay
- Differential diagnosis:
  - Kilppel-Trenaunay Syndrome – A triad of port-wine stain, varicose veins, and bony and soft tissue hypertrophy involving an extremity

Tuberous sclerosis

SIRIRAJ DERMATOLOGY ANNUAL Meeting 2024

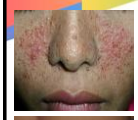

- Autosomal dominant inheritance (TSC1 and TSC2 gene)
- Incidence: 1:10,000 births
- Clinical triads: epilepsy, low intelligent, adenoma sebaceum
- Hamartomas in eyes, brains, kidneys, heart, lung
- Facial angiofibroma (adenoma sebaceum)
  - Appear at 2-5 years of age
  - 1-3 mm in diameter pink to red papules
  - Involve nasolabial folds
- Ash-leaf hypopigmentation
  - Earliest skin sign
- Shagreen patch
  - Lumbosacral connective nevus
- Periungual fibroma: Koenen tumor
- Gingival fibroma, dental enamel pits
- Fibrous plaque of the forehead


Multiple calcified subependymal nodules in a paraventricular location
Tuberous sclerosis
SIRIRAJ DERMATOLOGY ANNUAL Meeting 2024
2012 revised diagnostic criteria for tuberous sclerosis complex
Retinal hamartomas of tuberous sclerosis
Guttate leukoderma(confetti macules)
2012 REVISED DIAGNOSTIC CRITERIA FOR TUBEROUS SCLEROSIS COMPLEX (TSC)
Major features
Hypomelanotic macules (≥3, diameter ≥5 mm)
Facial angiofibromas (≥3) or fibrous cephalic plaque
Ungual fibromas (≥2)
Shagreen patch
Multiple retinal hamartomas
Cortical dysplasias (including tubers and cerebral white matter radial migration lines)
Subependymal nodules
Subependymal giant cell astrocytoma
Cardiac rhabdomyoma
Lymphangioleiomyomatosis
Angiomyolipomas (≥2; renal ≥ other organs, e.g. liver)
Minor features
"Confetti" skin lesions
Dental enamel pits (≥3)
Intraoral fibromas (≥2)
Retinal achromic patch
Multiple renal cysts
Non-renal hamartomas
Definite clinical diagnosis
• Either two major features* or one major feature plus ≥2 minor features
Possible clinical diagnosis
• Either one major feature or ≥2 minor features
Definite genetic diagnosis†
• Identification of a pathogenic mutation in either TSC1 or TSC2 in DNA from the blood or normal tissue
Key:
Cutaneous
Extracutaneous
*With the exception of lymphangioleiomyomatosis + angiomyolipomas.
†Genetic testing is recommended when the diagnosis of TSC is suspected but cannot be clinically confirmed, as well as to assist in genetic counseling and family planning. 10–25% of patients with TSC have no pathogenic mutation identified by conventional genetic testing, so a normal result does not exclude TSC unless a known pathogenic mutation in an affected relative is absent.
Bolognia 4th ed., 2018

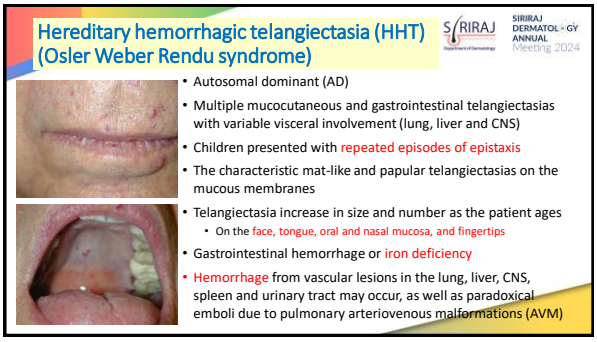
Hereditary hemorrhagic telangiectasia (HHT) (Osler Weber Rendu syndrome)
SIRIRAJ DERMATOLOGY ANNUAL Meeting 2024
• Autosomal dominant (AD)
• Multiple mucocutaneous and gastrointestinal telangiectasias with variable visceral involvement (lung, liver and CNS)
• Children presented with repeated episodes of epistaxis
• The characteristic mat-like and papular telangiectasias on the mucous membranes
• Telangiectasia increase in size and number as the patient ages
• On the face, tongue, oral and nasal mucosa, and fingertips
• Gastrointestinal hemorrhage or iron deficiency
• Hemorrhage from vascular lesions in the lung, liver, CNS, spleen and urinary tract may occur, as well as paradoxical emboli due to pulmonary arteriovenous malformations (AVM)

Lesions on "Neck and Trunk"
SIRIRAJ DERMATOLOGY ANNUAL Meeting 2024

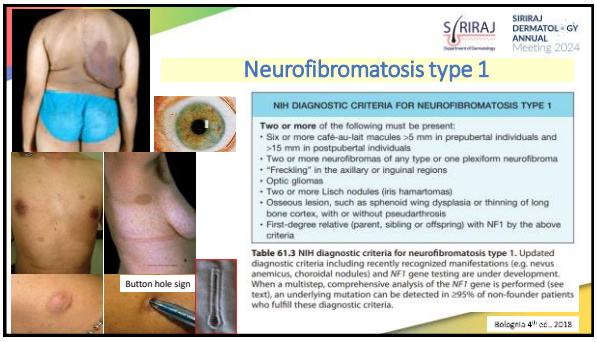
SIRIRAJ DERMATOLOGY ANNUAL Meeting 2024
Neurofibromatosis type 1
NIH DIAGNOSTIC CRITERIA FOR NEUROFIBROMATOSIS TYPE 1
Two or more of the following must be present:
• Six or more café-au-lait macules >5 mm in prepubertal individuals and >15 mm in postpubertal individuals
• Two or more neurofibromas of any type or one plexiform neurofibroma
• "Freckling" in the axillary or inguinal regions
• Optic gliomas
• Two or more Lisch nodules (iris hamartomas)
• Osseous lesion, such as sphenoid wing dysplasia or thinning of long bone cortex, with or without pseudarthrosis
• First-degree relative (parent, sibling or offspring) with NF1 by the above criteria
Table 61.3 NIH diagnostic criteria for neurofibromatosis type 1. Updated diagnostic criteria including recently recognized manifestations (e.g. nevus anemicus, choroidal nodules) and NF1 gene testing are under development. When a multistep, comprehensive analysis of the NF1 gene is performed (see text), an underlying mutation can be detected in ≥95% of non-founder patients who fulfill these diagnostic criteria.
Button hole sign
Bolognia 4th ed., 2018

Pseudoxanthoma elasticum

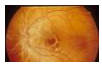

Angioid streak

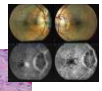

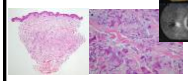

- Inherited disorder (recessive and dominant)
- CNT of the skin, eye cardiovascular system
- "Plucked chicken" appearance in flexural skin
- Angioid streak
- Calcification of elastic media of blood vessels: renal artery – hypertension, bleeding in GI and GU tract

Acanthosis nigricans

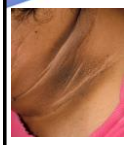

Tripe palms

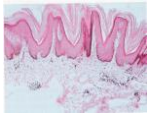

- Cutaneous marker, most commonly of insulin resistance and less frequently of genetic disorder and malignancy
- Symmetric hyperpigmented, hyperkeratotic verrucous plaques on intertriginous skin
- Tripe palms(acanthosis palmaris; pachydermatoglyphy)
  : >90% associate with malignancy
  - CA lung and CA stomach

Sweet syndrome (Neutrophilic dermatosis)

- **Criteria for diagnosis of Sweet syndrome**

  Major criteria
  1. Abrupt onset of typical cutaneous lesions
  2. Histopathology consistent with Sweet's syndrome

  Minor criteria
  1. Precede by one of the associated conditions
  2. Presence of fever and constitutional signs and symptoms
  3. Leukocytosis
  4. Excellent response to systemic corticosteroids

  Two major and **two minor** criteria are needed for the diagnosis
- **Associated conditions**
  - Hematologic malignancies: esp. AML
  - Drug induce: G-CSF
  - Infection: mycobacteria (TB, NTM)
  - Associated with adult-onset immunodeficiency syndrome (Interferon gamma autoantibody)
  - Pregnancy

Pyoderma gangrenosum (Neutrophilic dermatosis)

- Diagnosis by excluding other causes of similar appearing cutaneous ulcerations
- Sterile neutrophilic abscesses
- Between 50% and 70% of patients with PG have an associated diseases
- The most common associations are
  - Inflammatory bowel disease (ulcerative colitis or Crohn disease, 20–30%)
  - Arthritis (seronegative arthritis, spondylitis of inflammatory bowel disease or rheumatoid arthritis, 20%)
  - Hematologic diseases (in particular, acute > chronic myelogenous leukemia, hairy cell leukemia, myelodysplasia and monoclonal gammopathy (IgA), 15–25%).
- Pathergy: Ulcerations may occur after trauma or injury to the skin in 30% of patients

Calciphylaxis

SIRIRAJ DERMATOLOGY ANNUAL Meeting 2024

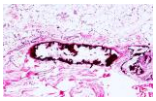

- Progressive cutaneous painful necrosis associated with small- and medium-sized vessel calcification
- Retiform purpura progressed to extensive necrosis of the skin
- Risk factors: Female, ESRD, obesity, DM, hyperparathyroidism, medications (calcium, vitamin D)
- Location: Abdomen, buttock and thigh
- Cutaneous findings:
  - Painful indurated plaque, nodules
  - Retiform purpura
  - Livedo reticularis
  - Digital gangrene
- Extracutaneous findings
  - Skeletal myopathy
  - Intestinal bleeding
  - Visual impairment

Blue toe syndrome

SIRIRAJ DERMATOLOGY ANNUAL Meeting 2024

- Clinical Differential Diagnosis retiform purpura with **"blue toes"**
  - **Vasculitis**
    - Polyarteritis nodosa
    - Hypersensitivity vasculitis (Autoimmune, Drug, Infection related)
  - **Vasculitis-mimics**
    - Embolism
    - Atheroemboli
    - Cardiac vegetation : IE
    - Thrombosis
    - Warfarin skin necrosis
    - Antiphospholipid syndrome
    - DIC

Lesions on "the Legs"

SIRIRAJ DERMATOLOGY ANNUAL Meeting 2024

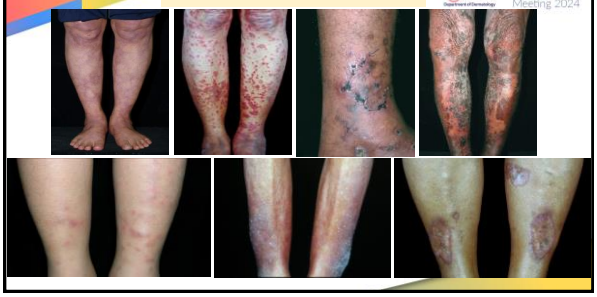

Livedo reticularis

SIRIRAJ DERMATOLOGY ANNUAL Meeting 2024

CAUSES OF LIVEDO RETICULARIS

Congenital livedo reticularis
- Cutis marmorata telangiectatica congenita

Acquired livedo reticularis

Vasospasm
- Cutis marmorata/physiologic livedo reticularis
- Primary (idiopathic) livedo reticularis
- Autoimmune connective tissue diseases (e.g. SLE)
- Raynaud phenomenon/disease

Vessel wall pathology
- Vasculitis
  - Cutaneous polyarteritis nodosa
  - Systemic polyarteritis nodosa
  - Cryoglobulinemic vasculitis
  - Autoimmune connective tissue disease-associated vasculitis (e.g. rheumatoid arthritis, SLE, Sjögren syndrome)
- Lymphocytic thrombophilic arteritis (may be variant of polyarteritis nodosa)
- Calciphylaxis
- Sneddon syndrome
- Deficiency of adenosine deaminase 2
- Livedoid vasculopathy (also intraluminal obstruction)

Intraluminal pathology
- Increased normal blood components
  - Thrombocythemia
  - Polycythemia vera
- Abnormal proteins
  - Cryoglobulinemia
  - Cryofibrinogenemia
  - Cold agglutinins
  - Paraproteinemia
- Hypercoagulability (see Table 105.9)
  - Antiphospholipid syndrome
  - Protein S and C deficiencies
  - Antithrombin III deficiency
  - Factor V Leiden mutation
  - Homocystinuria, hyperhomocysteinemia
  - Disseminated intravascular coagulation
- Thrombotic thrombocytopenic purpura
- Embolic
  - Cholesterol emboli
  - Septic emboli
  - Atrial myxoma
  - Nitrogen (decompression sickness)
  - Carbon dioxide arteriography
- Hyperoxaluria
- Intravascular histiocytosis

Other
- Medications (e.g. amantadine, norepinephrine, interferon)
- Infections (e.g. hepatitis C [vasculitis], *Mycoplasma* spp. [cold agglutinins], syphilis)
- Neoplasms (e.g. pheochromocytoma)
- Neurologic disorders (e.g. complex regional pain syndrome [reflex sympathetic dystrophy], paralysis)

PATTERN OF LIVEDO RETICULARIS VERSUS LIVEDO RACEMOSA

Patterns of livedo reticularis: (A) versus livedo racemosa (B).

Bolognia 4th ed., 2018

Palpable purpura (Cutaneous small-vessel vasculitis)

SIRIRAJ DERMATOLOGY ANNUAL Meeting 2024

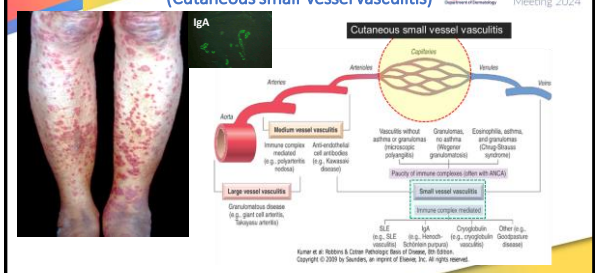

Livedoid vasculopathy

SIRIRAJ DERMATOLOGY ANNUAL Meeting 2024

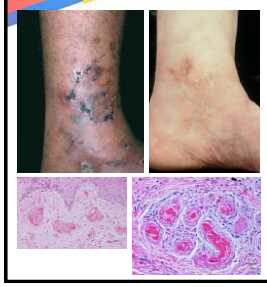

- Ischemic dermopathy characterized by a violaceous reticular or net-like mottling of the skin
- Pathogenesis: unknown
  - Altered control of coagulation
- Female predominance
- Clinical presentation
  - Painful punched-out ulcers
  - White, round or stellate scars
  - Livedo reticularis, telangiectasia
- Primary vs. Secondary form
  - Antiphospholipid syndrome
  - Chronic venous hypertension
  - Hypercoagulable state

Pellagra

SIRIRAJ DERMATOLOGY ANNUAL Meeting 2024

- Niacin (Vitamin B3) deficiency
- Risk factors: alcoholism, long-term diarrhea, carcinoid syndrome, Hartnup disease, and a number of medications such as isoniazid
- 3 Ds of dermatitis, diarrhea, dementia
- Cutaneous presentation: Photodermatitis, alopecia, and sores in the mouth
- Glove of Gaunlet : lesions on the dorsum of the hands
- Casal's necklace : lesions affect the upper central portion of the chest and neck
- Sometimes extend down over the sternum to create a "cravat"

Glove of Gaunlet

Casal's necklace

Erythema nodosum

SIRIRAJ DERMATOLOGY ANNUAL Meeting 2024

- Clinical presentation: Symmetric, tender, erythematous, warm nodules and raised plaques on the anterior aspect of lower extremities
- Acute onset, spontaneous regression, no ulceration
- Histology: Septal panniculitis without vasculitis
- Causes: Infections, drugs (oral pills), malignancy, miscellaneous conditions, Behcet's disease, sarcoidosis
- Rx: associated disorder, bed rest, NSAID
- Systemic corticosteroid are rarely indicated
- Differential diagnosis with deep vasculitis, and other panniculitis lesion

Condition associated with EN

Infections	
	Tuberculosis
	Tularemia
	Streptococcal infections
	Campylobacter
	Salmonella
	Histoplasma
	Yersinia
Drugs	
	Sulfonamides
	Penicillin
	Minocycline
	Salicylates
	Iodides
	Gold salts
	Oral contraceptives
Systemic diseases	
	Sarcoidosis
	Sweet's syndrome
	Behcet's disease
	Inflammatory bowel disease
	Carcinomas
	Leukemia
	Lymphoma
	Antiphospholipid antibodies

Cutaneous signs in thyroid diseases

SIRIRAJ DERMATOLOGY ANNUAL Meeting 2024

Hyperthyroidism: Grave disease

- Infiltrative ophthalmopathy (exophthalmos)
- Infiltrative dermopathy (pretibial myxedema)
- Acropachy

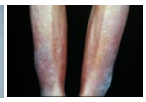

Hypothyroidism

- Generalized myxedema

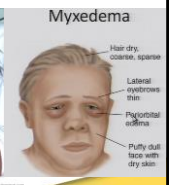

Cutaneous signs in Diabetes Mellitus

SIRIRAJ DERMATOLOGY ANNUAL Meeting 2024

Necrobiosis lipoidica diabeticorum

- Cutaneous marker for DM
- Solitary or multiple, unilateral/bilateral
- Common location: pretibial area
- 13-19% resolve spontaneously after 6-12 yrs
- Their persistence is independent of the patient's glycemic control
- 1/3 of NLD cases have DM, 1/3 with IFG, 1/3 with normal blood sugar level
- 0.3 % of DM cases have NLD

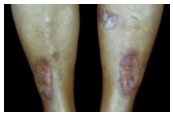

Scleredema diabeticorum

- Gradual onset of thick and hard skin on the back of the neck, shoulders, arms, and upper back
- A rare disorder, the exact cause is unknown
- Tend to occur in men with poorly-controlled diabetes who are obese, use insulin, and without other diabetic complications
- No specific treatment for scleredema
- Not cure

Cutaneous signs in Diabetes Mellitus

SIRIRAJ DERMATOLOGY ANNUAL Meeting 2024

Diabetic dermopathy (shin spot)

- The most common finding
- Not a specific marker; present in 30-60% of DM
- Bilaterally but not symmetrically
- Characteristic appearance of hyperpigmented, atrophic skin lesions, often grouped, on the lower extremities
- Effect of microangiopathy

Diabetic bullae

- Spontaneous tense blisters on hands and feet
- Spontaneous heal within 2-5 weeks
- Good circulation but may have peripheral neuropathy
- Heal with atrophic scar
- DDx with other cell-poor subepidermal blister
  - Bullous pemphigoid
  - EBA
  - PCT

SIRIRAJ DERMATOLOGY ANNUAL Meeting 2024

Cutaneous complications associated with DM

Macroangiopathy

- Atherosclerosis :

skin atrophy	hair loss
coldness of toes	nail dystrophy
pallor on elevation	
mottling on dependence	

Sign : dependent rubor with delayed return of color (> 15 seconds) after pressure has been applied to the skin

Microangiopathy

diabetic dermopathy	pigmented purpura
erysipelas-like erythema	NLD
periungual telangiectases	diabetic foot
nail changes	

Punctate keratosis on palms and soles

- History of CA tongue S/P excision 2 years ago
- Multiple cutaneous SCCs at head, neck, and trunk, and toes S/P excision
- No known underlying diseases
- History of herbal medicine 30 years ago

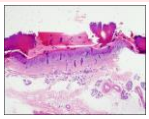

Diagnosis: Arsenical keratosis

Arsenical keratosis

- Important cutaneous findings of chronic arsenic toxicity
  - arsenicosis
- Precancerous condition
  - Corn-like, yellowish, hyperkeratotic papules and plaques on palms and soles
  - Progress to SCCs
- Awareness and high degree of suspicion are needed
- Onset duration: 4-40 years
- Etiology: Inorganic arsenic from contaminated groundwater, food crops, medications (Fowler's solution/1% Potassium arsenite, Chinese herbal medicine, and ayurvedic medicines), occupational exposure, tobacco

Chronic arsenicism (Chronic arsenic toxicities)

- **Cutaneous findings**:
  - Hypo-hyperpigmented macules in non-sun exposure area *(Raindrops on a dusty road)*
  - Punctate keratosis on palms and soles (arsenical keratosis)
  - Arsenic-induced skin cancers: Bowen disease, SCC, BCC, and Merkel cell carcinoma

Am J Med. 2017 Dec;130(12):1382-1384

Porphyria cutanea tarda

SIRIRAJ DERMATOLOGY ANNUAL Meeting 2024

A group of related disorders, deficient activity of heme synthetic enzyme uroporphyrinogen decarboxylase (URO-D) in the liver

M>F adult
Prevalence 1:10,000

Skin photosensitivity with blistering on sun-exposed areas skin fragility, hyperpigmentation, hyperthricosis

High levels of uroporphyrin in plasma and urine

SIRIRAJ DERMATOLOGY ANNUAL Meeting 2024

Q & A